

Percutaneous Biliary Drainage: A 12-year Experience

MOHAMED M. RAWAS, FRCP(C)

*Department of Radiology, King Khalid National Guard Hospital,
Jeddah, Saudi Arabia*

ABSTRACT. To report 12 years (108 patients, 273 procedures) experience and clinical outcome of percutaneous biliary drainage, with and without stent application, in benign and malignant obstruction. A retrospective study of patients who presented biliary obstruction and who had percutaneous biliary drainage, with or without stent application. The technical success of external biliary drainage (EBD), dual biliary drainage (DBD) and stent application was 97%, 91%, and 98%. EBD patients with obstructive jaundice and cholangitis (36) showed good clinical outcome in 67% and was poor in 33%. EBD patients with obstructive jaundice, (39) only showed good clinical outcome in 62%, fair in 31% and poor in 7%. The mean patency for soft stents is 32.7 and 7.4 months in benign and malignant strictures. The mean patency for metallic stents is 26.8 and 4.5 months in benign and malignant strictures. Adequate laboratory results were not obtained in (33) patients whose general condition improved after (EBD). The complication rate is 11% for (EBD) and (DBD), 20% for all stents. The 30-day mortality for (EBD) and (DBD) is 3% and none was noted post stent application. Percutaneous biliary drainage, with or without stent application, is useful in the diagnosis and management of patients with malignant or benign biliary tract obstruction.

Keywords: Percutaneous, Cholangiogram, Biliary drainage.

Introduction

Percutaneous biliary drainage is a known interventional radiology procedure. The initial description of the technique appeared in the late 1970s and early 1980s. Since then, there have been many developments that included internal biliary drainage and

Correspondence & reprint requests to: Dr. Mohamed M. Rawas, Department of Radiology, King Khalid National Guard Hospital, P.O. Box 9515, Jeddah 21423, Saudi Arabia.

Accepted for publication: 27 September 2000. Received: 26 January 2000.

different stent applications. This article reports a 12-year experience of EBD, DBD, and different stent applications. The clinical outcome of the procedures, as well as other parameters, are discussed and compared with the available literature.

Materials and Methods

Between January 1987 and December 1998 (12 years), percutaneous biliary drainage (PBD) was performed on 108 patients. Fifty-one patients with malignant stricture and 28 patients with benign strictures (mainly post-operative), 19 patients with choledocholithiasis, 5 patients had various other etiologies and with 5 patients a diagnosis was never obtained (Table 1). 123 EBDs were attempted on 108 patients and 78 DBDs were attempted on 64 patients. With DBD, a catheter with multiple holes is positioned through the obstruction between the duodenum and the external drainage bag (Fig.1, Plate A). 23 soft stents (Care-Coons Percuflex - Meditech) and 17 metallic stents were used on 36 patients. Of the 123 EBDs, there were 111 right and 12 left EBDs. The ages ranged from 1 to 100 years with a mean of 50.8 years. There were 60 female and 48 male patients. The initial EBD and stent insertions were performed as in-patient procedures, otherwise, the patients were seen in the Radiology Department as out-patients for attempts as DBD and transcatheter brush biopsy. The pre-procedural preparation included fasting for 6 hours, prothrombin, partial thromboplastin times and checking of platelets. An intravenous (IV) line of normal saline to keep the vein open was inserted. The patient received a single dose of IV antibiotics two hours before the procedure to cover against gram positive, gram negative, and anaerobic infections (Zei-nacef 750 mg, Gentamycin 80 mg, and Flagyl 500 mgs).

TABLE 1. The pathologic diagnosis in 103 patients with biliary obstruction.

Benign	No. of Patients	Malignant	No. of Patients
Post-op Str.	11	Cholangioca	25
Anastomosis Str.	16	Pancreas Ca	8
Chronic Pancreatitis	1	Liver Ca	4
Choledocholithiasis	19	Gall Bladder Ca	3
Caroli Disease	1	Ampulla of Ca	5
Hydatid Cyst	1	Colon Ca	2
Biliary Atresia	1	Stomach Ca	2
Chedochal Cyst Type	1	Haemangiopericystoma	2
Schelerosing Choangitis	1	-	-
Total	52	Total	51

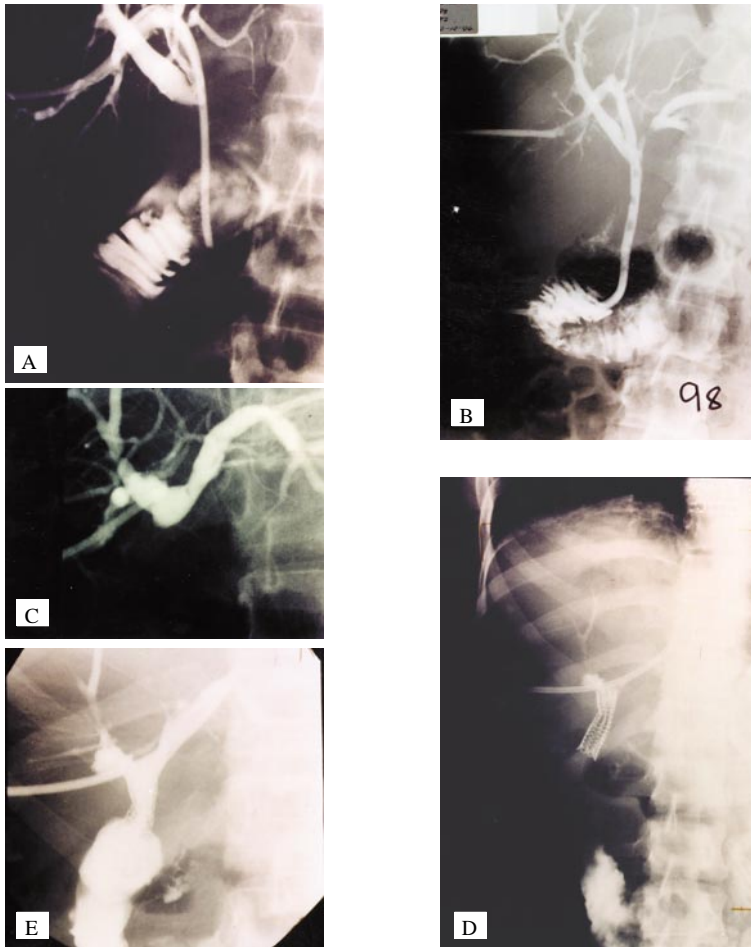


Fig.1. Plate A: Showing DBD catheter with multi side holes is positioned through biliary ducts to bowel. The other end is connected to the external drainage bag. Note the catheter cannulation through a posterior subsegmental bile duct. Plate B: Showing final cholangiogram after soft stent insertion in-patient with anastomotic stricture. Plate C: Showing complete obstruction at choledochoduodenostomy. Plate D: Striker stent in place. Plate E: Final cholangiogram.

The procedures were done under fluoroscopic guidance. Pethidine 50 mg IV and Phenergan 50 mg IM were used for sedation and analgesia. Local anaesthetic of 1% Zylocaine without adrenaline was infiltrated locally at the skin puncture site. Three pediatric patients, aged 1, 5, and 9 years, were done under general anaesthesia. A percutaneous transhepatic cholangiogram (PTC) is obtained first by using 21 Chiba needle. After biliary ducts visualisation, cannulation of segmental or sub-segmental duct (usually posterior segment of the right lobe) was performed (Fig.1) using Hawkins biliary set (Cook). The EBD catheter (9Fr Kifa) was then shaped using boiled water and introduced. On one side, a hole was made close to the catheter tip. The catheter was advanced to above the obstruction site for external drainage.

Attempts, to achieve DBD, were performed after a few days to weeks of external drainage. This may be obtained after 1 to 4 attempts. In some patients, DBD was obtained at the time of EBD. Balloon dilatation of the stricture and stent insertion was done within one week of DBD. Transcatheter brush biopsy was done at the time of DBD if no diagnosis was obtained by other means (surgery and fine needle aspiration biopsy).

All patients not going for DBD had ampullary balloon dilatation (10 mm diameter) or mechanical stone crushing a few days after initial EBD. Some patients had only EBD, after which they had a surgical operation, referred back to original hospital or were lost to follow-up. Patients were assessed for improvement in their general condition, cholangitis, and laboratory parameters. Complications and mortality are discussed.

The results of EBD and DBD were classified as Good, Fair, and Poor. Good results mean more than 50% reduction in serum bilirubin, reduction in alkaline phosphatase and SGOT, improved general condition (itching, malaise, appetite, skin and eye colour). Fair results mean less than 50% reduction in serum bilirubin, with some reduction in alkaline phosphatase and SGOT and some improvement in general condition. Poor results mean no significant change observed in laboratory parameters or general condition. For cholangitis, good results mean resolution of fever and chills, with white blood count close to normal range. Poor results mean no recovery from cholangitis was observed.

Results

All patients were subjected to EBD. Sixty-four patients moved to the second step of DBD. Forty stents were applied in 36 patients (Table 2). Other procedures included ampullary balloon dilatation in 9 patients for choledocholithiasis. One of these patients needed mechanical stone crushing due to large size of the stones. Three other patients had 4 mechanical stone crushing only. Transcatheter brush biopsies were performed in 16 patients.

Most of the EBD approaches were right-sided, 11/123 procedures. The left-sided approach was performed in 12/123 procedures. In 2 patients, the left EBD (does not appear in (Tables 2 & 3) and was initially planned and performed to avoid right hydatid cyst and tumour invaded right lobe respectively. The other 10 left EBDs were due to failed right EBDs in 5 patients, isolated left ductal system due to hilar malignancy in 5 patients, and 1 of these patients was done twice. The left EBD procedures were all technically successful. This is probably due to readily accessible ductal systems from anterior sub costal approach.

TABLE 2. Different percutaneous transhepatic biliary procedures performed in 108 patients.

Procedures	No. of Procedures
EBD	123
DBD	78
Stents:	40
a) Percuflex Carey-Coons	23
b) Metallic:	
1. Percuflex Carey-Coons	7
2. Gianturco-Rosch Z	5
3. Wall	5
Brush biopsy	16
Dilatation of ampulla	9
Mechanical crushing of stones	5
Stricture dilatation and splinting	2

TABLE 3. Reasoned failure of EBD and DBD procedures and patient outcome.

	No.	Pathology	No. of Attempts	Reason of Failure	Patient Outcome
RIGHT	1.	Caroli	2	Multiple stricture	(L) DBD
EBD	2.	Anastomotic str.	1	Minimal dilatation	(L) Stricker stn.
	3.	Cholangio Ca.	2	Technical	(L) Soft stn.
	4.	Cholangio Ca.	1	Acute angle	(L) Soft stn.
	5.	Cholangio Ca.	3	Silk ligature	(L) DBD
	6.	Post-op str	3	Silk ligature	Surgery
RIGHT	7.	Post-op str	3	Silk ligature	Surgery
DBD	8.	Post-op str	3	Silk ligature	Surgery
	9.	Post-op str	3	Tight stricture	Surgery
	10.	Cholangio Ca.	1	Tight stricture	Surgery (Utube)
	11.	Cholangio Ca.	4	Tight stricture	Right EBD extensive tumour

The total number of failed EBD and DBD procedures was 11/201 with technical success of 190/201 (95%). The right EBD technical success was 119/123 (97%). The four failed procedures (Table 3) were with a 4-year child with Caroli disease. The second patient was obstructed dilated biliary tree but predominantly on the left side, with minimal right ductal dilatation. The third and fourth patients had hilar cholangiocarcinoma with dilated left ductal system. In all 4 patients, left EBDs were successful (Table 3). Three patients went on to have stent application through the left side

and 1 patient had left EBD. The clinical outcome of EBD in patients with and without cholangitis is detailed (Table 4 & 5).

TABLE 4. Result of EBD in patients with jaundice and cholangitis.

Correlates	No.	Good	Poor
Anastomatic str.	9	7	2
Post-op str.	2	0	2
Choledocolithiasis	5	4	1
Caroli disease	1	0	1
Biliary atresia	1	1	0
Schlerosing cholangitis	1	0	1
	19	12/19 (63%)	7/19 (37%)
Cholangio Ca.	9	7	2
Ampullary Ca.	2	2	0
Liver Ca.	1	0	1
Pancreatic Ca.	2	1	1
Stomach Ca.	1	1	0
	15	11/15 (73%)	4/15 (27%)
No diagnosis	2	1	1
TOTAL	36	24/36 (67%)	12/36 (33%)

The DBD technical success was 71/78 (91%). Seven failed procedures (Table 3) were encountered. In 1 patient, acute angle between entry point to biliary tree and stricture site was believed to be the reason. This patient had a successful DBD from the left side. Three patients with silk ligature found around the CHD at operation. The other 3 patient failures were due to tight sticture. Multiple attempts were made in two of them. The third patient had only one attempt after which a U tube was inserted surgically.

The most commonly encountered pathology in this series was benign surgery-related stricture (27 patients). Patients came for biliary drainage after the original surgery (post-operative strictures) or post-surgical anastomosis for ductal injury (anastomotic stricture) (Table 1). 8/11 post-operative stricture patients presented post-open cholecystectomy and 3/11 post-laparoscopic cholecystectomy. The anastomotic strictures were 11/16 choledocho-jejunostomy, 3/16 choledocho-duendenostomy, 1/16 choledocho-choledochal anastomosis (liver transplant), and 1/16 hepatico-jejunostomy.

The patients presented 1 week to 5-years after the operation. The length of time was related to severity of the injury, *i.e.*, patients with CHD ligature presented within the

first two weeks after the operation. Patients with adequate surgical anastomosis may present many years after with anastomotic strictures.

In patients presenting with cholangitis (Table 4), the benign obstructions (mainly anastomotic stricture and choledocholithiasis) showed good response of cholangitis resolution in 63%. The 2 patients who presented post-operation did not respond and died of septic shock. The patients suffered from CHD transection and choledochojejunostomy for pancreatic carcinoma respectively. In patients with cholangitis and malignant obstructions, the response of cholangitis resolution was generally good (73%), particularly in cholangio-carcinoma and ampullary carcinoma.

The patients who came to EBD due to jaundice only and no cholangitis show better results in benign obstruction (78% good results) versus (47% in malignant obstruction (Table 5).

TABLE 5. Results of EBD in patients with jaundice.

	No.	Good	Fair	Poor
Anastomotic str.	4	2	0	2
Post-op str..	4	4	0	0
Choledocolithiasis	8	7	1	0
Chronic pancreatitis	1	1	0	0
Hydatid cyst	1	0	1	0
	18	14/18 (78%)	2/18 (11%)	2/18 (11%)
Cholangio Ca.	6	4	1	1
Pancreatic Ca.	4	1	3	0
Liver Ca.	3	0	3	0
Ampulla Ca.	2	2	0	0
Colon Ca.	2	1	1	0
Gall Baldder Ca.	1	0	1	0
Lymphoma	1	1	0	0
	19	9/19 (47%)	9/19 (47%)	1/19 (5%)
No diagnosis	2	1	1	1
TOTAL	39	24/39 (62%)	12/39 (31%)	3/39 (7%)

Seven benign strictures received soft stents (12 & 14 Fr) (Fig. 1, Plate B). The range of potency was 7-84 months and a mean of 32.7 months. Thirteen benign strictures received metallic stents (Gianturco-Rosch Z, Stricker, Wall) . (Fig. 1, Plates C, D, E) shows the range of potency is 3-96 months, with a mean of 26.8 months. One of these

patients had recurrent obstruction due to tissue proliferation (epithelial hyperplasia) at the distal end of the stent after 66 months. It was treated by a metallic stent insertion and remained patent for 18 months (Fig. 2, Plates A, B, C).

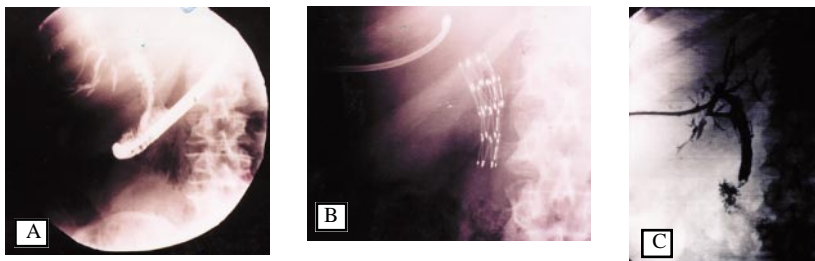


Fig. 2. Plate A: Endoscopic cholangiogram showing recurrent narrowing at the distal end of the stent. Plate B: Second stent in place. Plate C: Final cholangiogram.

Sixteen malignant strictures received soft stents. The range of potency is 2-17 months with a mean of 6.4 months. Four malignant strictures received metallic stents. The range of potency is 2-10 months with a mean of 4.5 months. Metallic stent application for malignant strictures was practised late in the series. The potency rates are summarised in Table 6.

TABLE 6. Stents mean potency in months.

	Benign str.		Malignant str.	
	No.	Mean	No.	Mean
Soft	(7)	32.7	(16)	6.4
Metallic	(11)	26.8	(4)	4.5

The complications related to EBD, DBD and stents include cholangitis, migration, obstruction, haemobilia, resticture, and other less frequent complications (Table 7).

Attacks of cholangitis were noted with catheter drainage and internal stents, probably related to insufficient EBD and reflux of bowel content to bile ducts. Four of the six patients who had EBD & DBD had multiple attacks of cholangitis, treated conservatively. The last patient had cholangio carcinoma with a non-functioning endoscopic stent that could not be removed. Hepatic abscess was noted at the proximal stent end. The abscess drained percutaneously. The 2 patients with stents who had cholangitis were one with Stricker stent for palliation of a malignant obstruction and on with percutflex soft stent for recurrent intrahepatic biliary stones after persistent failure of multiple ERCP and surgery trials to clear his choledocholithiasis.

Migration (displacement) of drainage catheter was noted in 7 patients. In 3/7, reinsertion was performed. In 1/7, the patient went to surgery for his choledocholithiasis. The initial EBD in this 80-year old male patient was to improve hepatic func-

tion and general condition before surgery. Reinsertion was not necessary. In 1/7, displacement and reinsertion occurred twice (76-year old male with metastatic pancreatic carcinoma). Reinsertion of displaced catheter failed in 1/7 patients with chlerosing cholangitis. The last patient showed displaced catheter to right subphrenic space with continued bile drainage from the subphrenic bilima. The patient died before reinsertion.

TABLE 7. Complications related to EBD, DBD, and stents.

Complication	EBD & DBD	Stents
Migration	7	2
Obstruction	2	2
Cholangitis	6	2
Haemobilia	4	-
Recurrent stricture	2*	1
Broken balloon catheter	1	-
Bile leak at insertion site	-	1
Death (30-day mortality)	6	-
Septicaemia	-	-
Bile peritonitis	-	-
Haemoperitoneum	-	-
TOTAL	28/201 (14%)	28/201 (14%)
Morbidity	11%	20%
Mortality	3%	

*Balloon Dilatation Only

Migration was noted in a patient with a soft stent. The anchoring silk threads were inadvertently cut surgically. The stent was lost in the stool. Another patient had his Z stents migrate upward from the stricture site. Both patients received metallic stents for their anastomotic strictures.

The catheter obstruction and subsequent interruption of drainage was noted and new catheter insertion was performed in the patient with Caroli disease. The second patient had catheter obstruction during a long EBD period (4 months) in a patient anastomotic stricture awaiting stenting. The two obstructed stents were both soft type and 10 and 17 months of follow-up. Four patients had haemobilia related to EBD and DBD; 2 from the right and 2 from the left side catheters. One patient had severe haemobilia during attempts of the left DBD. The manipulation was stopped and the catheter clamped for 24 hours. The left DBD was achieved the next day through the anastomotic stricture. The second patient had transient haemobilia after achieved the left DBD.

Spontaneous resolution was noted. The other 2 patients had transient haemobilia after the right EBD, with spontaneous resolution. In all cases, no further radiological or surgical intervention was needed.

Two patients had recurrent strictures. Both were anastomotic strictures and were dilated with 10mm diameter balloon. The stricture site was splinted by nelaton 16FR catheter for three months. The strictures recurred after 5 and 21 months respectively. Both were re-drained and stented by soft stents. One patient with a metallic stent had recurrent obstruction at the distal stent end and required another metallic stent application (Fig. 2). The dilatation balloon was detached from the catheter shaft in one patient. The balloon was manipulated to the duodenum where it was expelled naturally per rectum. Bile leak at insertion site was noted in 1 patient after the left side soft stent placement. This was due to an inadequate stent position, with the proximal end of the stent close to the liver surface (extraductal). The stent was repositioned.

Thirty-day mortalities were seen in 2/6 patients after EBD. Both had cholangitis and septicemia post-surgery (open cholecystectomy with CHD transection, choledochojejunostomy for pancreatic cancer). Revised surgery was attempted after EBD. Both died 5 and 6 days after EBD in septic shock. One had cholangio carcinoma, the other anastomotic stricture. One patient out of six had cholangitis and sepsis progressed to septic shock and death in 9 days, despite right EBD. The last patient was the one with hydatid syst and left EBD. He died from sepsis after 19 days. The hydatid cyst was treated surgically and was communicating to the biliary tree. The 3 patients who had operations after EBD are not true 30-days post-procedural mortality.

Balloon dilatation of ampulla was done in 9/19 patients with choledocholithiasis. In 4/9 patients, the check cholangiogram 4-14 days later showed no biliary stones. All 4 patients had previously failed endoscopic papillotomy and manipulation. Five out of nine patients had no previous endoscopic intervention. One patient had mechanical crushing of larger than 8 mm stones. Four out of nine patients had normal cholangiogram 3-20 days later. One out of nine patients went to surgery for persistent stones.

Ten out of nineteen patients with choledocholithiasis had EBD but no balloon dilatation of the ampulla. Three out of ten had stone mechanical crushing. Two out of three showed no stones on cholangiogram 3 and 9 days later. One out of three showed persistent fragments and went to surgery. One patient of this group had previously failed endoscopic papillotomy and manipulation. Seven out of ten patients had surgery 5-21 days post EBD. Two out of seven had additional reasons for surgery (post-op biliary fistula and choledochocolonic fistula). One out of seven patients of this group had previous endoscopic intervention.

The conclusion of the experience with choledocholithiasis is that balloon dilatation of the ampulla with or without previous papillotomy seems to be effective in clearing stones of 8 mm or less in size. Larger stones can be mechanically crushed before balloon dilatation. EBD can be useful pre-operatively in patients with choledocholithiasis.

Transatheter biliary brush biopsy was performed in 16 patients for diagnosis (Fig. 3, Plates A, B). Ten out of sixteen biopsies showed malignancy. Seven of those were cholangio carcinoma, 1 ampullary carcinoma, 1 recurrent ampullary carcinoma, and 1 post whipple recurrent pancreatic carcinoma. Four out of sixteen biopsies showed no malignancy and were proven benign stricture. In 2/16 biopsies, no diagnosis could be obtained and proved by FNA to have cholangio carcinom and pancreatic carcinoma respectively.

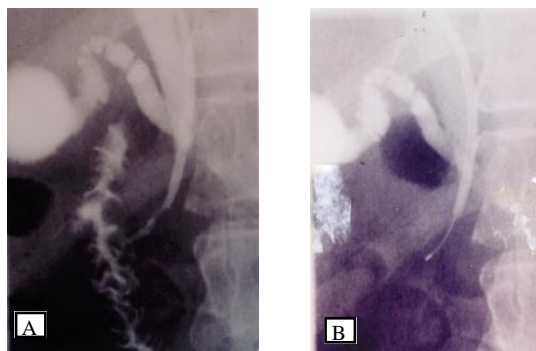


Fig. 3. Plate A: Cholangiogram via EBD catheter with tip at the stricture site. Plate B: The brush biopsy is within the stricture.

Discussion

Percutaneous biliary drainage is a known procedure. It was initially described in the late 1970s and early 1980s^[1]. Experience has accumulated over the last two decades, with further evolution of its techniques, results and complications^[2,3,4]. The technical success of EBD was reported to be above 90%^[2,3]. The overall biliary decompression success in this patient series is 100%. The 4 patients who failed right EBD procedures were successfully drained through the left EBD. Adequate biliary decompression was achieved in all patients.

The clinical results of biliary drainage were judged using criteria resembling that of Gazzangia *et al*^[3]. It was noted in the results presented here that 24/36 of the patients with jaundice and cholangitis responded well to EBD along with other supportive measures, such as IV antibiotics. This supports the data of other authors^[2,3,4]. In patients with jaundice only, the results obtained in this series indicated that 62% were good and 31% had a fair outcome which is slightly less than that of Gazzaniga^[3] (81.5% and 15% respectively).

The complication of 14% in this series compared favourably to 15.4% of Gazzaniga^[3]. No haemoperitoneum, bile peritonitis or drainage-induced septicaemia was noted. This is probably due to selective cannulisation of segmental ducts peripheral in the liver and avoiding enteral duct punctures in the liver hilum.

The true 30-day procedure-related death noted in the series was 1.5%. The recorded mortalities were related to EBDs being ineffective in altering the course of the original disease.

Percutaneous metallic stent application is a known form of management for benign biliary strictures^[5-8]. The potency rate is reported at 87% at 1 year and 68.7% at 3 years^[5,6]. During the period of available follow-up on our patients, the mean potency rate was 26.8 months (Table 6). Further follow-up, unfortunately, cannot be obtained. Of the patients who were referred back to their original hospitals after having stent insertion, only 1/13 patients needed re-intervention and a second stent insertion, due to epithelial hyperplasia and stenosis at the distal end of the stent after 66 months. The high mean potency rate of soft stents in benign strictures in this series (32.7 months) is mainly due to the large stent size (12-14F). The known potency rate of 10F stents is a few months to one-year^[9]. When our patients were present with cholangitis, conservative management was implemented. This was successful in most patients. The stent was replaced only after percutaneous or endoscopic cholangiogram proved obstructed stent.

The treatment strategy adopted of internal stent insertion for benign strictures is multi-factorial. My initial experience with 2 patients showed recurrent stricture after repeated balloon dilatation and external catheter stenting (16F) for 4 months. Patient acceptance of such treatment (long external stenting and repeated interventions) was quite discouraging. Approximately half of our patients are referred from remote hospitals. It has been shown from previous experience that patients are subjected to increased discomfort and the treatment may continue with dwelling catheter in place for 6 to 12 months^[7,10,11]. The internal soft stent used in this series remains in place as long as it is patent. When obstructed, it can be removed and/or replaced, if needed, endoscopically or percutaneous.

Our mean potency rate for soft stents is 6.4 months. This agrees with the previously reported experience^[9]. Other authors have reported occlusion rates of 6 - 23%^[12,13]. The implementation of expendable metallic stents in patients with malignant biliary stricture is a well-established method of palliation^[5-15]. The reported potency varied from 5.8 to 7 months and occlusion occurred in 7-24%. The mean potency rate of 4.5 months in this series needs to be looked at with caution. The number of stents is only four and patient follow-up was only 2 -10 months. Further experience and longer period of follow-up will most likely improve the potency rate.

In conclusion, percutaneous biliary drainage in skilled hands is a very useful method in the management of obstructive jaundice, with and without cholangitis. Metallic stents are a useful tool in palliation of malignant biliary disease and show promising results in benign stricture. Large size soft stents remain a good method to stent being strictures and can be easily removed or replaced. Balloon dilatation of the ampulla, with or without mechanical stone crushing, has been effective in choledocholithiasis.

Transcatheter brush biopsy of biliary stricture is a good method, added to FNA and surgery, to obtain tissue diagnosis in biliary tract obstruction.

References

- [1] **Ferrucci JT, Freeny PC, Stark DD, Foley WD, Mueller PR, May G, Burhenne HJ.** Advances in hepatobiliary radiology. *Radiology* 1988; **168**(2): 319-338.
- [2] **Ishikawa Y, Oishi I, Miyai M, Kishimoto T, Miyamura S, Sagayama T, Morigaki T, Yamashita T, Itoh N.** Percutaneous transhepatic drainage: experience in 100 cases. *J Clin Gastroenterol* 1980; **2**(3): 305-314.
- [3] **Gazzaniga GM, Faggioni A, Bandanza G, Filauro M.** Percutaneous transhepatic biliary drainage: twelve years experience. *Hepatogastroenterol* 1990; **37**(5): 517-523.
- [4] **Akiyama H, Okazaki T, Takashima I, Satoh S, Ryan T, Iwamori S, Hidaka T, Morio K, Okuhara T.** Percutaneous treatments for biliary disease. *Radiology* 1990; **176**(1): 25-30.
- [5] **Coons H.** Metallic stents for the treatment of biliary obstruction: a report of 100 cases. *Cardiovasc Intervent Radiology* 1992; **15**(6): 367-374.
- [6] **Maccioni F, Rossi M, Salvatori FM, Ricci P, Bezzi M, Rossi P.** Metallic stents in benign biliary strictures: three-year follow-up. *Cardiovasc Intervent Radiology* 1992; **15**(6): 360-366.
- [7] **Rossi P, Bezzi M, Salvatori FM, Maccioni F, Porcaro ML.** Recurrent benign biliary strictures: management with self-expanding metallic stents. *Radiology* 1990; **175**(3): 661-665.
- [8] **Adam A.** Metallic biliary endoprosthesis. *Cardiovasc Intervent Radiology* 1994; **17**(3): 127-132.
- [9] **Mygind T, Itennild V.** Expandable metallic endoprosthesis for biliary obstruction. *Acta Radiologica* 1993; **34**(3): 252-257.
- [10] **Moore AV Jr., Illescas FF, Mills RR, Wertman DE, Heaston DK, Newman GE, Zuger JH, Salmon RB, Dunnick NR.** Percutaneous dilation of benign biliary strictures. *Radiology* 1987; **163**(3): 625-628.
- [11] **Williams HJ, Bender CE, May GR.** Benign post-operative biliary strictures: dilatation with fluoroscopic guidance. *Radiology* 1987; **163**(3): 629-634.
- [12] **Kaufman SL.** Percutaneous palliation of unresectable pancreatic cancer. *Surg Clin N Am* 1995; **75**(5): 989-999.
- [13] **Lammer J, Neumayer K.** Biliary drainage endoprosthesis: experience with 201 placements. *Radiology* 1986; **159**(3): 625-629.
- [14] **LaBerge JM, Doherty M, Gordon RL, Ring EJ.** Hilar malignancy: treatment with an expandable metallic transhepatic biliary stent. *Radiology* 1990; **177**(3): 793-797.
- [15] **Lammer J, Klein GE, Kleiner R, Hausegger K, Einspieler R.** Obstructive jaundice: use of expandable metal endoprosthesis for biliary drainage. Work in Progress. *Radiology* 1990; **177**(3): 789-792.

بزل قنوات الكبد المرارية من خلال الجلد خبرة ١٢ عاماً

محمد محمد رواس

قسم الأشعة ، مستشفى الملك خالد للحرس الوطني ،
جدة - المملكة العربية السعودية

المستخلص. تم تسجيل دراسة خبرة ١٢ عاماً والفائدة السريرية في ١٠٨ مريض و ٢٧٣ عملية بزل مراري من النوع ذو التوصيلة الداخلية وبدونه، ذلك في مرضى التضيق والانسداد المراري الحميد والحيث. تم إجراء دراسة استرجاعية لمرضى التضيق والانسداد المراري الذين خضعوا لعملية البزل المراري للقنوات الكبدية والذين انتهوا بدون أو بتوصيلة داخلية. أثبتت النتائج نجاح الطريقة فنياً للبزل الخارجي أو المزدوج أو التوصيل الداخلي ٩٧٪ و ٩١٪ و ٩٨٪ على التوالي. التحسن السريري لمرضى الانسداد المراري المصحوب بالتهاب (٣٦ مريضاً) كان جيداً في ٦٧٪ وضعيفاً في ٣٣٪. التحسن السريري لمرضى الانسداد المراري غير المصحوب بالتهاب (٣٩ مريضاً) كان جيداً في ٦٢٪ وبسيطاً في ٣١٪ وضعيفاً في ٧٪. متوسط العمل التصريفي للتوصيلات الداخلية المعدنية كان ٢٦,٧ و ٥,٥ شهراً في الانسدادات الحميدة والحيثية على التوالي. لم نحصل على بيانات معملية كافية في ٣٣ مريض ولكن لوحظ تحسن في الحالة العامة لهؤلاء المرضى بعد البزل الخارجي. نسبة التعقيدات لعملية البزل كانت ١١٪ للخارجي والمزدوج و ٢٠٪ لكل أنواع التوصيلات الداخلية. إن عملية البزل للقنوات المرارية بدون أو بتوصيلة داخلية ذو فائدة في التشخيص والعلاج لمرضى الانسدادات المرارية الحميدة والحيثية على حد سواء.