

Popliteal vein aneurysm

H. A. Al Zahrani

Department of Cardiovascular Surgery, Al Noor Specialist Hospital, Makkah, Saudi Arabia

The successful management of a popliteal vein aneurysm in a 25-year-old Saudi man is described. An extensive review of the English literature revealed another 11 similar cases.

Keywords: popliteal vein aneurysm

Venous aneurysms are rare compared with arterial aneurysms and were first mentioned in the literature by Harris¹ in 1926. All major veins may be involved including the popliteal vein. To the best of the author's knowledge, only 11 cases of popliteal vein aneurysm have been described in the English literature²⁻¹⁰. The present case report adds one more. The possible clinical presentations and management of this condition are discussed.

Case report

A 25-year-old Saudi male teacher was referred to the author's vascular clinic complaining of a painless swelling on the lower part of his right thigh and extending to the popliteal region over the previous few months. The swelling became bigger after standing for long periods and decreased in size with elevation of the leg. His past medical history was uneventful apart from a mild dull aching pain involving the affected limb. An extensive systemic review was normal.

Physical examination revealed the patient to be a well, young, non-obese man. The only abnormal finding was a compressible right popliteal swelling which extended to the lower part of the thigh. There was a significant difference in circumference of both lower limbs in this area. The mass was slightly tender and measured about 6 cm wide × 15 cm long. There was no evidence of any other venous abnormalities. Chest examination showed no significant abnormality. To identify the nature of the mass the patient underwent Doppler ultrasonography which revealed a very dilated popliteal vein consistent with the possibility of a popliteal vein aneurysm. This was confirmed by an ascending venogram which showed a fusiform popliteal vein aneurysm extending from the knee level for approximately 20 cm upwards.

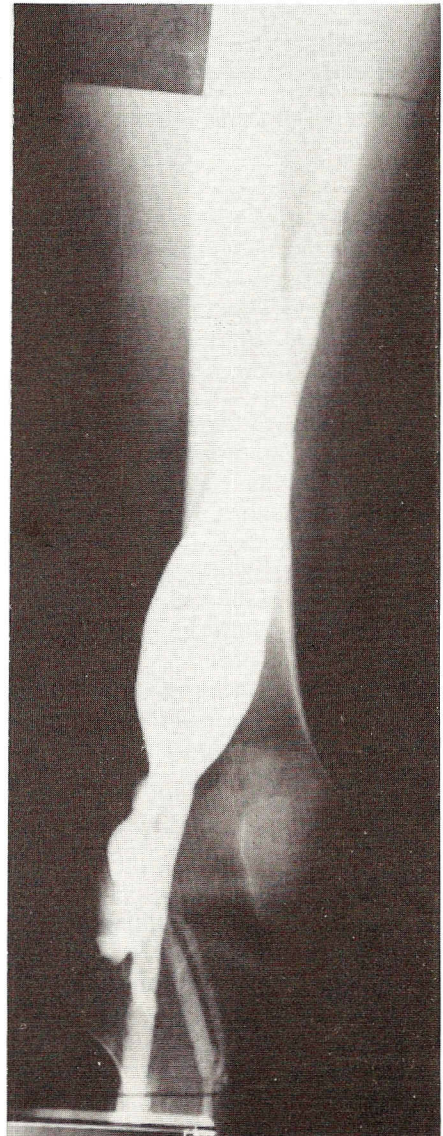


Figure 1 Preoperative ascending venogram showing a right fusiform popliteal vein aneurysm with no evidence of thrombosis formation

Correspondence to: Dr H. A. Al Zahrani, Al Noor Specialist Hospital, PO Box 6251, Makkah Al Mukarramah, Kingdom of Saudi Arabia

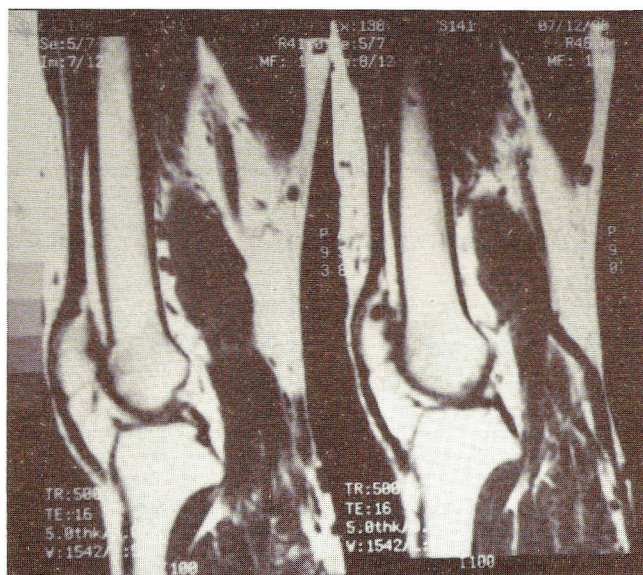


Figure 2 Preoperative magnetic resonance imaging scans confirming the previous findings

There was no evidence of thrombus formation (*Figure 1*). Magnetic resonance imaging was also requested for scientific purposes (*Figure 2*). A ventilation–perfusion scan excluded any evidence of pulmonary embolism associated with this aneurysm. However, the patient was administered aspirin 300 mg daily to prevent possible embolization.

The patient was admitted and underwent ligation of the popliteal vein proximally in the adductor canal and distally just below the knee via a medial approach. The contralateral long saphenous vein was used to bypass the occluded segment by anastomosing it in an end-to-side fashion distally and then proximally to the superficial femoral vein at the upper end of the adductor canal. The patient was fully heparinized during and immediately after surgery.

Two weeks later, the patient again received the same dose of aspirin and was advised to wear supportive venous stockings. He was symptom-free 3 months after operation and the graft was patent on Doppler examination.

Discussion

Primary venous aneurysm as an entity is rare and not mentioned in most texts^{1,2}. In 1928, Harris¹ described an aneurysm of the jugular vein in a 5-year-old girl. Venous aneurysms can affect any vein in the body and are usually true aneurysms². Although the cause of these aneurysms is unknown, some reports suggest that they are developmental in origin, perhaps resulting from a weakness in the elastic fibres of the vessel wall⁶.

Popliteal vein aneurysms are very rare with only 11 cases reported in the English literature^{2–10}. They are

mainly true aneurysms and only one pseudoaneurysm was reported in the literature¹¹. The present case adds one more to the previously reported cases (*Table 1*). In contrast to previous reports the present review shows equal incidence in males and females. The age of patients ranges from 17 to 75 years with a mean of 44.5 years. Seven of the 12 patients (58%) presented with dyspnoea and/or chest pain and another three (25%) had syncopal episodes. Two patients (17%) were symptomless (i.e. presented only with a popliteal mass). Therefore this possibility should be kept in mind and included in the differential diagnosis of the popliteal fossae mass. Diagnosis depends on a high index of suspicion, particularly if the mass is compressible. Plethysmography and hand-held Doppler examination are unhelpful^{2–10}. Duplex scanning when available is very useful, although the gold standard investigation is venography¹⁰. Magnetic resonance imaging was performed in the present patient for the author's research purposes and may be indicated in selected cases as it has the advantages of being non-invasive and will not precipitate embolism in a thrombosed popliteal vein aneurysm⁷.

Once the diagnosis is made, surgical correction is indicated in view of the frequent incidence of a fatal complication associated with these aneurysms (i.e. pulmonary embolism). Indeed, ten of the 12 reported cases had evidence of pulmonary embolism at presentation. Several surgical procedures are described in the literature. Resection of the aneurysm with venous bypass was hailed as the procedure of choice. Exclusion by ligation of the aneurysm and bypass was performed in the present case. Perhaps the latter procedure is an acceptable alternative to the direct procedure, particularly in long-extending aneurysms. If so, it is better to use the contralateral great saphenous vein to ensure good venous drainage. To the best of the author's knowledge, this procedure was performed for the first time in treating these aneurysms.

Table 1 Review of the English literature of 12 cases of popliteal vein aneurysms

Authors	Year	Patient age (years)	Sex	Presentation	Pulmonary embolism
Federman <i>et al.</i> ³	1977	37	F	Syncope	+
		62	M	Dyspnoea	+
Harolds and Friedman ²	1977	17	F	Mass	–
Dahl <i>et al.</i> ⁴	1979	59	F	Dyspnoea	+
Persson <i>et al.</i> ⁵	1980	37	M	Syncope	+
Chahlaoui <i>et al.</i> ⁶	1981	75	F	Chest pain	+
Donald and Edwards ⁷	1982	59	M	Dyspnoea	+
Gallagher and Hageman ⁸	1985	48	M	Syncope	+
Ross <i>et al.</i> ⁹	1988	37	F	Dyspnoea	+
		50	M	Chest pain	+
Dawson <i>et al.</i> ¹⁰	1991	28	F	Chest pain	+
Present case		25	M	Mass	–

Acknowledgements

The author thanks Dr Abdulaziz Abdu Al Aal (Department of Surgery) and Miss Merida 'Mariam' Harayin (his departmental English secretary) for their help in the preparation of this manuscript.

References

1. Harris RI. Congenital venous cyst of the mediastinum. *Ann Surg* 1926; **88**: 953-6.
2. Harolds JA, Friedman MH. Venous aneurysm. *South Med J* 1977; **70**: 219-21.
3. Federman J, Anderson ST, Rosengarten DS, Pitt A. Pulmonary embolism secondary to anomalies of deep venous system of the leg. *Br Heart J* 1977; **39**: 547-52.
4. Dahl JR, Freed T, Burke M. Popliteal vein aneurysm with recurrent pulmonary thromboembolism. *JAMA* 1979; **236**: 2531-2.
5. Persson BG, Donner M, Peterson B, Eklof B, Wintzel K. Aneurysm of the popliteal vein as a cause of pulmonary embolism. *Acta Med Scand* 1980; **208**: 407-10.
6. Chahlaoui J, Julien M, Nadeau PU, Bruneau L, Roy P, Sylvestre J. Popliteal venous aneurysm: a source of pulmonary embolism. *AJR Am J Roentgenol* 1981; **136**: 415-16.
7. Donald IP, Edwards RC. Fatal outcome from popliteal venous aneurysm associated with pulmonary embolism. *Br J Radiol* 1982; **55**: 930-1.
8. Gallagher JJ, Hageman JH. Popliteal vein aneurysm causing pulmonary embolus. *Arch Surg* 1985; **120**: 1173-5.
9. Ross GJ, Violi L, Barber LW, Vugic I. Popliteal venous aneurysm. *Radiology* 1988; **168**: 721-2.
10. Dawson KJ, Hehir DJ, Hamilton G. Popliteal vein aneurysm. *Eur J Vasc Surg* 1991; **5**: 697-9.
11. Noon GP, Zamora JL, Pratt CM, Willingham I. Popliteal vein pseudoaneurysm: a case report. *Surgery* 1984; **96**: 942-5.

Paper accepted 17 May 1994